

Expression of retinoblastoma gene product in respiratory epithelium and sinonasal neoplasms: relationship with p16 and cyclin D1 expression

M.J. Schwerer¹, A. Sailer¹, K. Kraft¹, K. Baczako² and H. Maier³

¹Department of Pathology, Military Hospital Ulm, Ulm/Donau, Germany, ²Institute of Pathology, Ulm/Donau, Germany and

³Department of Otorhinolaryngology, Head and Neck Surgery, Military Hospital Ulm, Ulm/Donau, Germany

Summary. Transition from G₁ to S phase of the cell cycle is mediated by interactions between the Retinoblastoma gene product (pRb), p16, and cyclin D1. To determine the expression of these proteins in the sinonasal mucosa immunohistochemistry was carried out on archived tissue sections from 46 patients (37 men, 9 women, age range 17 to 82 years, median 55 years). Nuclear immunostaining for these proteins was assessed and the expression rates (percentages of immunoreactive nuclei) in normal respiratory epithelium, inverted sinonasal papillomas, cylindrical (oncocyctic) sinonasal papillomas, and squamous cell carcinomas were compared.

Normal respiratory epithelium showed significantly higher pRb expression in surface cells compared to basal cells ($p < 0.05$). In contrast, abundant pRb expression in surface and basal cells was detected in columnar differentiation in sinonasal papillomas and adjacent mucosa. Cuboidal and squamous metaplasia in inverted papillomas showed significantly reduced pRb expression in surface cells compared to columnar epithelium in inverted papillomas ($p < 0.05$, respectively). Expression of p16 was detected in all epithelial cell layers of normal respiratory epithelium, sinonasal papillomas, and adjacent mucosa. Cuboidal and squamous metaplasia in inverted papillomas showed increased p16 expression in surface cells compared to columnar epithelium in inverted papillomas ($p < 0.05$ between squamous metaplasia and columnar epithelium). Sinonasal squamous cell carcinomas showed the coexpression of pRb and p16. Expression rates of cyclin D1 higher than 10% were detected only in invasive carcinomas but not in carcinoma in situ, sinonasal papillomas or respiratory epithelium. Conclusively, pRb expression accompanies terminal differentiation in columnar surface cells. Expression of pRb in proliferating basal cells is present

in sinonasal papillomas and adjacent mucosa but not in normal respiratory epithelium. Cuboidal and squamous metaplasia in inverted papillomas involves downregulation of pRb expression along with increased p16 expression in surface cells. Sinonasal squamous cell carcinomas coexpress pRb and p16. Overexpression of cyclin D1 in sinonasal lesions is confined to invasive squamous cell carcinomas.

Key words: Respiratory epithelium, Sinonasal lesions, pRb, P16, Cyclin D1

Introduction

The mucosal surface of the sinonasal tract is characterised by a pseudostratified respiratory epithelium. This involves columnar ciliated surface cells, mucin-producing goblet cells as well as small, round to ovoid basal cells (Balogh, 1997). Inverted papillomas and cylindrical cell papillomas represent benign neoplastic lesions which demonstrate an expansive downward proliferation of sinonasal epithelium (Michaels and Young, 1995). The epithelium in inverted papillomas undergoes a stepwise metaplastic process along with disease progression; ciliated columnar epithelium is replaced by cuboidal epithelium and finally squamous metaplasia (Michaels and Young, 1995; Schwerer et al., 2001). In contrast, cylindrical cell papillomas are characterised by a unique histological appearance with tall, slender, columnar surface cells. Microcysts filled with mucous or nuclear debris are abundantly present within the epithelium (Michaels and Young, 1995). The association between sinonasal papillomas and squamous cell carcinomas which was already reported by Hapman and Billroth in 1883 is now commonly accepted. Larger studies identified malignant progression in up to 25% of inverted papillomas (Lawson et al., 1995; Jardine et al., 2000; Klimek et al., 2000; Thorp et al., 2001). In contrast to inverted papillomas and cylindrical cell papillomas the exophytic

(fungiform) variant of sinonasal papilloma is not associated with an increased malignant potential (Shanmugaratman and Sobin, 1991).

Dysfunction of several regulatory pathways in the cell cycle have recently been identified in sinonasal carcinogenesis (Califano et al., 2000). However, the role of the Retinoblastoma pathway of cell cycle control has not yet been investigated in sinonasal lesions. The Retinoblastoma gene product (pRb) is widely expressed in human tissues. Underphosphorylated pRb serves as a negative regulator by prohibiting progression from mid-G₁ to S-phase. Phosphorylation of pRb on serine and threonine residues, a process which is triggered by cyclin D1/Cyclin-dependent kinase(CDK)4 and/or CDK6 complexes leads to the dissociation of transcription factors including proteins of the E2F family. Consequently, E2F stimulate the expression of genes required for S-phase control including c-myc, N-myc, and dihydrofolate reductase. The p16 protein product of the CDKN2/MTS1/INK4 tumour suppressor gene located on chromosome band 9p21 binds to and inhibits CDK4- and CDK6-mediated phosphorylation of pRb by releasing cyclin D1 from its association with CDK4/CDK6, subsequently targeting cyclin D1 for destruction. Feedback autoregulatory loops have been identified in which activated as well as inactivated pRb modulates p16 and Cyclin D1 expression (Goodrich et al., 1991; Müller et al., 1994; Lukas et al., 1995; Yeager et al., 1995; Fang et al., 1998). Dysregulation of pRb-dependent cell cycle control is associated with unrestricted proliferation and carcinogenesis in a plethora of human tissues including oral and laryngeal squamous cell carcinomas (Bartkova et al., 1995; Pavelic et al., 1996; Pande et al., 1998; Ambrosch et al., 2001; Papadimitrakopoulou et al., 2001; Akervall et al., 2002).

In the present study the expression of pRb, p16, and cyclin D1 was investigated in the respiratory mucosa. Compared to other techniques immunohistochemistry allows the phenotypic localisation of pRb, p16, and cyclin D1 expression at cellular level. Significant concordance between the immunostaining results for the Retinoblastoma pathway proteins and the findings from Western blotting has recently been demonstrated (El-Naggar et al., 1999). Hence, we applied immunohistochemistry to investigate differences in pRb, p16, and cyclin D1 expression between respiratory epithelium and sinonasal squamous cell carcinomas. Further, the expression of these proteins in inverted papillomas and cylindrical cell papillomas which represent sinonasal papillomas with an increased malignant potential was studied.

Material and methods

Tissue specimens and standard histology

Paraffin-embedded tissue specimens from 46 patients were retrieved from the archives of the

Department of Pathology, Military Hospital Ulm, Ulm/Donau, Germany. The patient population comprised 37 males (80.4%) and 9 females (19.6%). Patients were 17 to 82 years of age, with a median of 55 years. Four serial slides, 5µm thick, were cut and one of them was stained with Haematoxylin and eosin (H&E). Histological examination for adequacy of lesional tissue and classification of specimens was carried out using the H&E-stained slides. The remaining three slides were used for immunohistochemistry.

Study groups

Normal respiratory epithelium was studied using seven cases with either normal histology or minimal chronic inflammation. Specimens showing features of more than minimal chronic inflammation, including dense lymphocytic infiltration, lymphofollicular hyperplasia, basal membrane thickening, and/or submucosal fibrosis, were excluded from this group. Further, specimens with signs of active inflammation, including neutrophilic infiltration, edema, and/or hemorrhage as well as samples with concomitant sinonasal papillomas or squamous cell carcinomas, were excluded. According to the definitions for lesions of the upper aerodigestive tract given by the World Health Organization, inverted papillomas and cylindrical cell papillomas were classified into two respective groups (Shanmugaratman and Sobin, 1991). Twenty-three cases of inverted papillomas and eight specimens of cylindrical cell papillomas were assessed. Cases associated with concomitant sinonasal squamous cell carcinomas were excluded from these groups. Within inverted papillomas, epithelial components with columnar differentiation were present in nineteen cases. Cuboidal epithelium was present in twenty-one cases, and squamous epithelium in fourteen cases. These distinct histological components were evaluated in respective subgroups. In seventeen cases of inverted papillomas and cylindrical cell papillomas, adjacent, non-papillomatous respiratory epithelium was available and studied in a respective group. Eight cases of sinonasal squamous cell carcinomas were evaluated. Among them were three cases with carcinoma in situ and five cases with invasive carcinomas. Classification of specimens was carried out by two independent observers (M.J.S. and K.B.). Differences between their individual reports were resolved by re-examination and consensus.

Immunohistochemistry

The streptavidin-biotin-peroxidase technique for immunohistochemistry was applied as previously reported (Schwerer et al., 2001). Briefly, sections were dewaxed in xylol and through graded alcohols and then immersed in a citrate buffer solution (0.01 M sodium citrate, pH 6.0). Sections were boiled in a microwave oven at 500 W (six times, 5 minutes each) for antigen

pRb in sinonasal lesions

retrieval. After hydrogen peroxidase treatment (0.3% in absolute methanol for 30 minutes) to block the endogenous peroxidase activity, the slides were processed for staining of pRb using the monoclonal antibody Anti-Human pRb, clone Rb1 (DAKO, Hamburg, Germany) at a 1:25 dilution. Immunostaining for p16 and cyclin D1 was performed using the monoclonal antibodies p16 F-12, clone sc-1661 (Santa Cruz Biotechnology Inc., Heidelberg, Germany), 1:500 dilution, and Anti-Human cyclin D1, clone DCS-6 (DAKO), 1:50 dilution. The primary antibodies were visualised using the LSAB2 Kit (DAKO) with 3,3'-diaminobenzidine as a chromogen. All incubations were carried out at room temperature for 30 minutes except for incubation with the chromogen which was carried out for 5 minutes. Between all incubations repeated washing of the slides was done using TBS. Counterstaining was performed by incubation with Mayer's haemalaun for 1 minute followed by washing with tap water. Finally the slides were mounted using glycerin gelatin. For pRb and p16, external positive controls were provided by employing sections from an oral mucosa biopsy showing moderate to severe dysplasia. For cyclin D1 sections from a moderately differentiated oral squamous cell carcinoma previously known to express cyclin D1 were used as an external positive control. Negative controls were performed using normal horse serum at the same dilutions.

Assessment of immunohistochemistry

Assessment of staining results was carried out independently from the histological classification of specimens. All slides were reviewed by two observers (M.J.S. and A.S.) under light microscopy. A minimum of 400 cells were evaluated in each section. A cell was considered positive if there was a visibly detectable signal within the nucleus. Only nuclear staining was regarded as positive staining, regardless of possible staining also in the cytoplasm. Inflammatory cells and reactive stromal cells served as internal positive controls. Expression rates of pRb, p16, and cyclin D1 were calculated from the number of cells with immunopositive nuclei compared to the total number of cells (nuclear expression rates for pRb, p16, and cyclin D1). Staining intensity was not considered in the evaluation of the expression rates. Expression rates were precisely assessed as negative staining (only negative nuclei) or positive staining (more than 0.0% of positive nuclei) without the use of a predefined cut-off-level for a positive staining result.

In normal respiratory epithelium and mucosa adjacent to sinonasal papillomas basal and surface cells were assessed. In inverted papillomas and cylindrical cell papillomas basal, parabasal, suprabasal, and surface cells were evaluated, respectively. Representative areas within squamous cell carcinoma in situ and on the invasion front of invasive squamous cell carcinomas were investigated without further distinction between

epithelial cell layers.

Evaluation and statistics

In all study groups the expression rates of pRb, p16, and cyclin D1 were compared between basal and surface cells. Further, immunoreactivity for these proteins was compared between normal respiratory epithelium, mucosa adjacent to sinonasal papillomas, cylindrical cell papillomas, histological subgroups within inverted papillomas, and sinonasal squamous cell carcinomas. Statistics were compiled using the Wilcoxon-test for matched pairs to analyse different expression rates between basal and surface cells as well as different immunoreactivities between the histological subtypes of inverted papillomas. Statistical analysis of inverted papillomas involved only specimens with more than one type of epithelial differentiation. The Wilcoxon, Mann, and Whitney-test for non-matched pairs was applied to analyse different immunoreactivities between normal respiratory epithelium and mucosa adjacent to sinonasal papillomas. For both tests significance was set at $p < 0.05$ (Ramm and Hofmann, 1982).

Results

Expression of pRb in respiratory epithelium and sinonasal papillomas

In normal respiratory epithelium an abundance of pRb was detected in the nuclei of surface cells. Significantly lower nuclear expression rates were observed in basal cells ($p < 0.05$). Respiratory epithelium adjacent to sinonasal papillomas showed significantly higher nuclear expression rates of pRb in basal cells compared to normal mucosa ($p < 0.05$, Figs. 1a, 2a).

Cylindrical cell papillomas and columnar epithelium in inverted papillomas demonstrated abundant nuclear immunostaining for pRb in all layers of the epithelium (Figs. 3a, 4a). In contrast, cuboidal and squamous epithelium in inverted papillomas showed significantly lower nuclear expression rates of pRb of surface cells compared to basal cells ($p < 0.05$, respectively, Fig. 4c). The differences between nuclear pRb expression in surface cells of cuboidal and squamous epithelium compared to columnar epithelium in inverted papillomas were significant ($p < 0.05$, respectively). Staining results are summarised in Table 1.

Expression of p16 in respiratory epithelium and sinonasal papillomas

Abundant nuclear expression rates of p16 in basal cells were observed in all groups of respiratory epithelium and sinonasal papillomas. Nuclear expression rates of p16 in surface cells were either comparable or slightly lower compared to basal cells in all specimens (Figs. 1b, 2b, 3b). In the nuclei of surface cells in inverted papillomas increasing expression rates of p16

*pRb in sinonasal lesions***Table 1.** Expression rates (in %) of Retinoblastoma and p16 gene products in respiratory mucosa and sinonasal papillomas.

	RETINOBLASTOMA GENE PRODUCT (pRb)				p16			
	surface	suprabasal	parabasal	basal	surface	suprabasal	parabasal	basal
<i>Normal respiratory epithelium (n=7, all specimens negative for cyclin D1):</i>								
total	74.3			9.6	71.9			88
<i>Respiratory epithelium adjacent to papillomas (total: n=17, cyclin D-1 positive: n=8):</i>								
total	86.5			80.5	78.5			88.1
Cyclin D 1 pos.	79.8			82.6	75.4			84.9
Cyclin D 1 neg.	95.7			80.2	78.5			89.1
<i>Cylindrical cell papillomas (total: n=8, cyclin D 1 positive: n=6):</i>								
total	95.4	95.5	96	94.1	87.5	86.2	86.4	85.8
Cyclin D 1 pos.	95.4	95.5	96.15	95.1	65.6	70.4	55.3	71
Cyclin D 1 neg.	90.9	89.8	92.6	93	92	91.7	95.7	91.4
<i>Inverted papillomas., columnar epithelium (total: n=19, cyclin D 1 positive: n=13):</i>								
total	86.1	87.4	91.7	93.6	81.5	88.4	91.7	93.1
Cyclin D 1 pos.	85.4	84	91.8	93.7	76.8	77.9	88.3	91.8
Cyclin D 1 neg.	92.1	90.9	93	90.8	85.7	92.5	96.3	98.6
<i>Inverted papillomas, cuboidal epithelium (total: n=21, cyclin D 1 positive: n=15):</i>								
total	12.7	51.8	95.4	97.8	93.7	94.2	95	94.8
Cyclin D 1 pos.	14.6	48.5	93.1	95.6	90.4	92.4	94	93.6
Cyclin D 1 neg.	11.8	72.3	98.2	98.9	96.7	98.8	99.6	100
<i>Inverted papillomas, squamous epithelium (total: n=14, cyclin D 1 positive: n=10):</i>								
total	25.7	62.3	100	100	96.7	95.3	95.2	95.7
Cyclin D 1 pos.	24	59.3	100	100	96.7	93.9	94.8	95.7
Cyclin D 1 neg.	28	71.6	97.4	97.9	96.2	98	96.4	95.6

"pos.": positive; "neg.": negative.

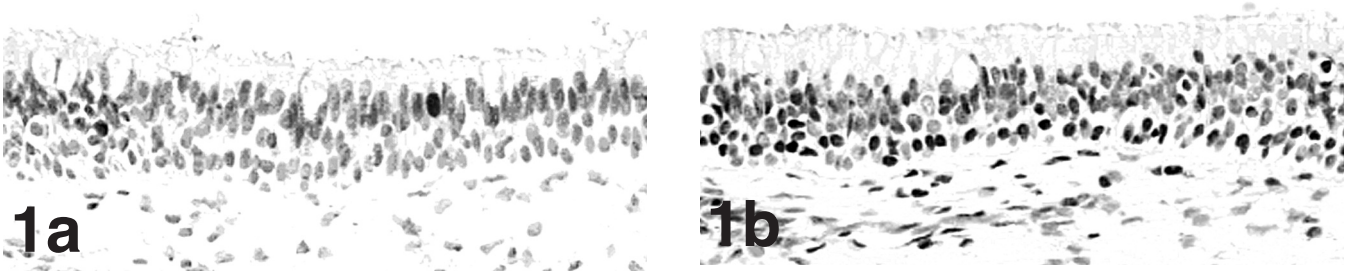


Fig. 1. Normal respiratory epithelium from a 19-year-old man. **a.** Nuclear expression of Retinoblastoma gene product (pRb) in this specimen is strongly restricted to a subset of surface cells. **b.** Nuclear expression of p16 involves the majority of basal cells along with a subset of surface cells. Serial slides from the same biopsy. x 200

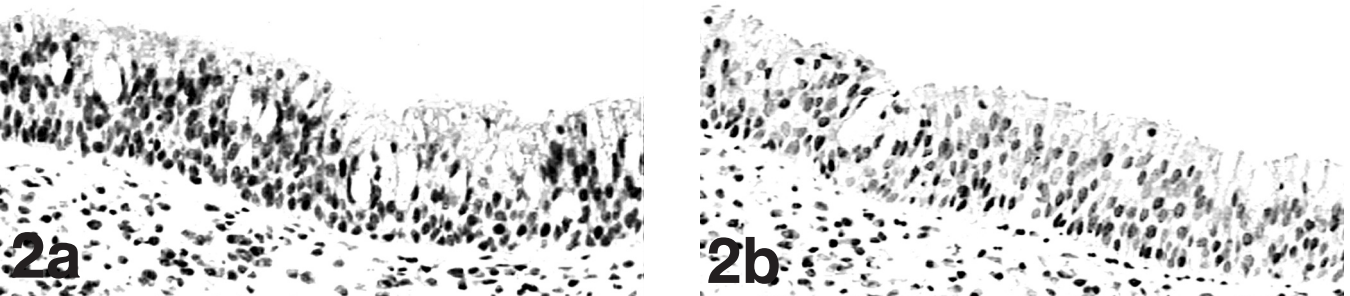


Fig. 2. Non-papillomatous nasal mucosa adjacent to an inverted papilloma in a 43-year-old man. Nuclear immunoreactivity for pRb (**a**) and p16 (**b**) is present in basal as well as surface cells of the epithelium. Serial slides from the same tissue section. x 200

pRb in sinonasal lesions

were detected from columnar to cuboidal epithelium and finally to squamous metaplasia (Fig. 4b,d). The difference in nuclear p16 expression in surface cells of

squamous epithelium compared to columnar epithelium in inverted papillomas was significant ($p < 0.05$). Staining results are demonstrated in Table 1.

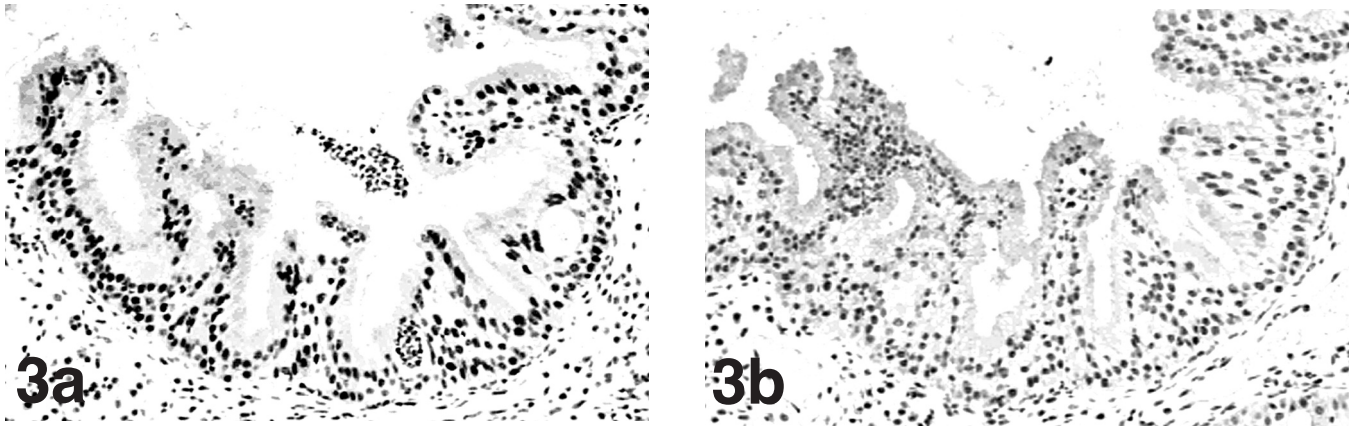


Fig. 3. Cylindrical cell papilloma from a 56-year-old man. Nuclear expression of pRb (a) and p16 (b) involves the majority of cells in all epithelial cell layers. Serial slides. x 125

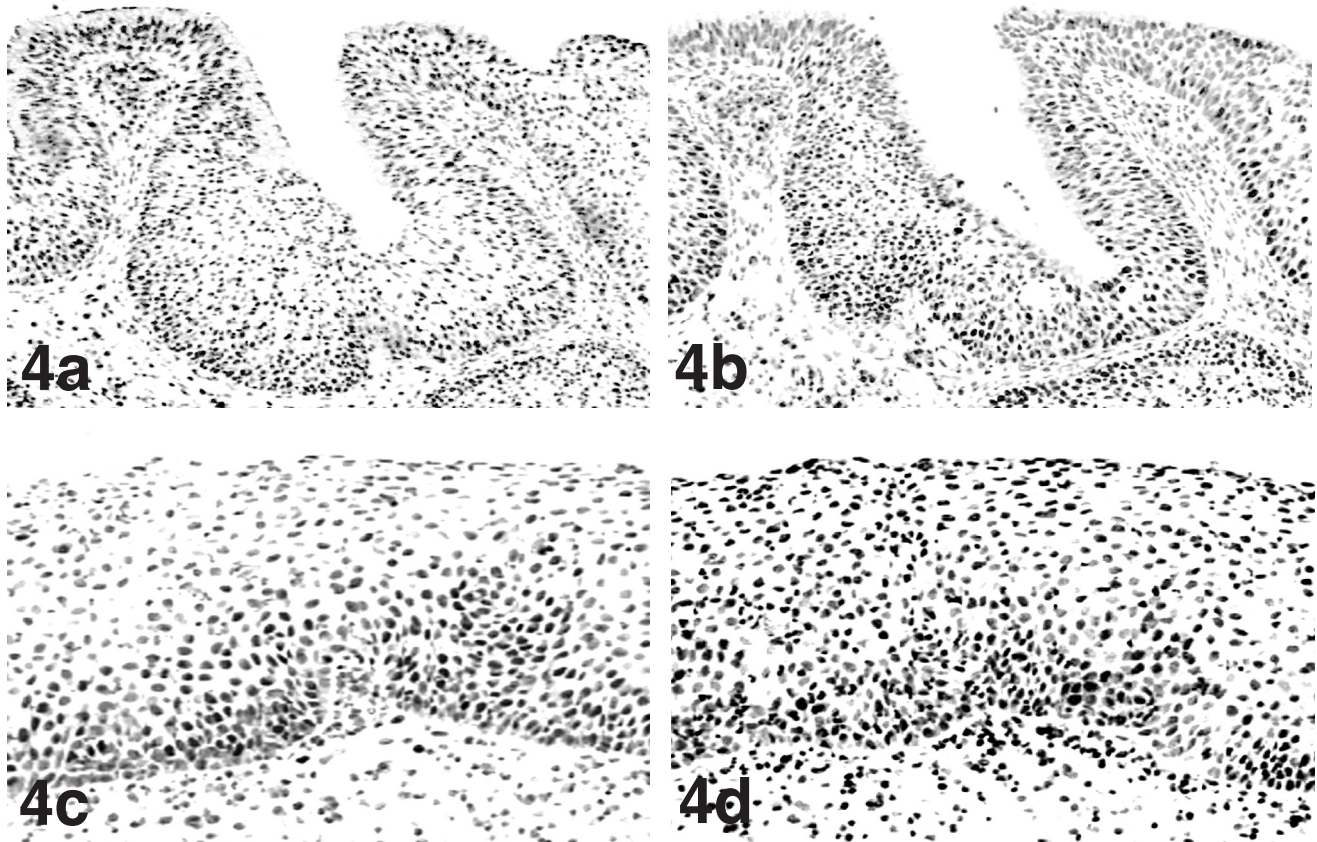


Fig. 4. Inverted papilloma from a 38-year-old man. Nuclear expression of pRb (a) and p16 (b) in columnar epithelium (serial slides). Note immunopositivity for both proteins in all epithelial cell layers. Squamous epithelium from the same specimen immunostained for pRb (c) and p16 (d). Serial slides. Note lower expression of pRb in the nuclei of surface cells compared to basal cells in squamous epithelium (c). Increased nuclear immunoreactivity for p16 is present in surface cells of squamous epithelium (d) compared to columnar epithelium (b). a,b, x 100; c, d, x 200

Expression of pRb and p16 in sinonasal squamous cell carcinomas

All sinonasal squamous cell carcinomas showed nuclear immunoreactivity for pRb as well as p16 (Figs. 5a,b). The expression rates of both proteins were highly variable in both squamous cell carcinoma in situ as well as in invasive squamous cell carcinomas. Staining results are presented in Table 2.

Expression of cyclin D1 in respiratory epithelium and sinonasal lesions

Normal respiratory epithelium was constantly negative for cyclin D1 expression. As shown in Table 1

Table 2. Expression rates (in %) of Retinoblastoma gene product (pRb), p16, and cyclin D1 gene product in sinonasal squamous cell carcinomas.

CASE NUMBER	HISTOLOGY	pRb	p16	CYCLIN D1
1	CIS	21.5	100	0
2	CIS	97.3	86.7	0.1
3	CIS	96.6	95.7	0.2
4	invasive	91.8	100	0
5	invasive	31.3	58	36.2
6	invasive	63.8	82.3	53.8
7	invasive	55.9	86.3	56.4
8	invasive	94.3	11.2	42.1

"CIS": squamous cell carcinoma in situ; "invasive": invasive squamous cell carcinoma.

nuclear immunoreactivity for cyclin D1 was present in a subset of cases of respiratory epithelium adjacent to sinonasal papillomas, cylindrical cell papillomas, and inverted papillomas. In all cases immunoreactivity was restricted to the nuclei of basal and parabasal cells and comprised less than 10% of cells (data not shown). No differences in pRb and p16 expression were found between cyclin D1-positive versus negative specimens. As shown in Table 2 squamous cell carcinomas in situ demonstrated either the absence of cyclin D1 or minimal expression rates of this protein. Four out of five invasive squamous cell carcinomas showed nuclear cyclin D1 expression in more than 10% of tumour cells (Fig. 5c).

Discussion

Surface cells of normal respiratory epithelium showed significantly higher expression rates of pRb compared to basal cells. The basal cells represent the regenerative compartment of the sinonasal epithelium. Epithelial turnover involves dividing precursor cells which undergo terminal differentiation along with their integration into the surface cell layer (Balogh, 1997; Guichard et al., 1998). In resting cells pRb prevents the G₁ to S-phase transition of the cell cycle (Goodrich et al. 1991; Fang et al. 1998). Hence, our findings indicate an association between pRb expression and terminal differentiation in columnar surface cells. Similar concepts have been proclaimed for other stratified epithelia including human oral and laryngeal squamous epithelium (Pavelic et al. 1996; Pande et al., 1998; El-Naggar et al., 1999; Ambrosch et al., 2001). In addition,

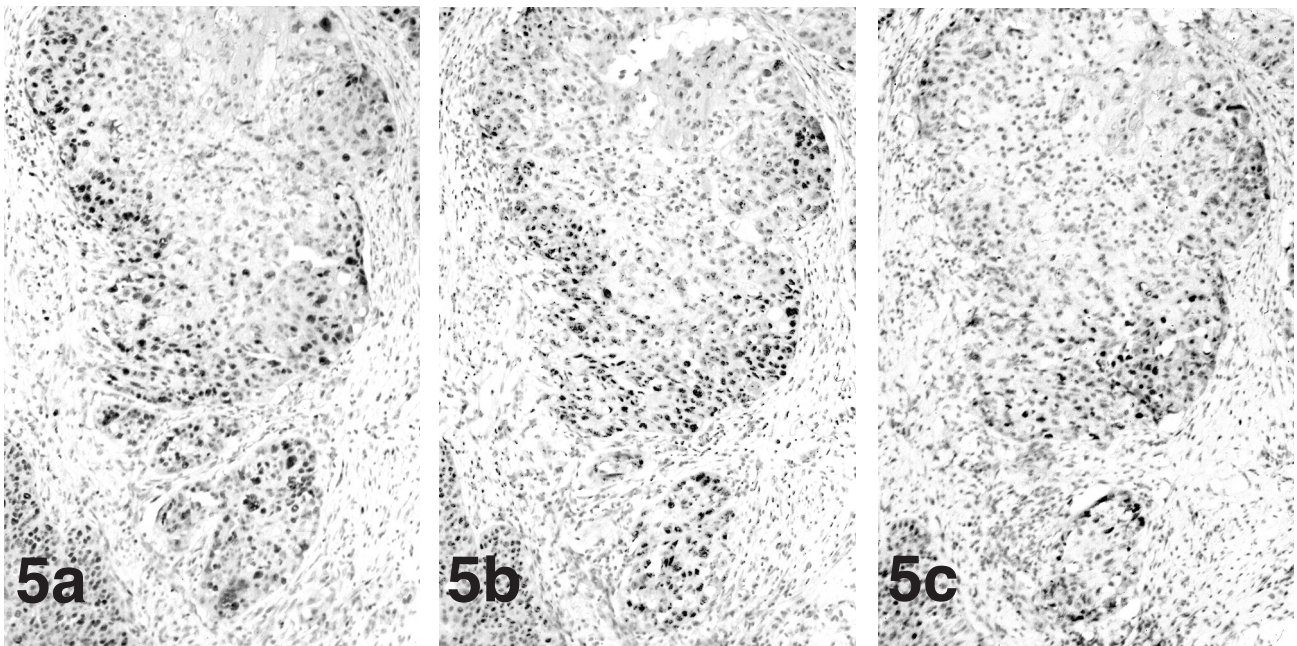


Fig. 5. Invasive squamous cell carcinoma from a 62-year-old man. Note coexpression of pRb (a) and p16 (b). Immunostaining for both proteins as well as the expression of cyclin D1 (c) predominantly involve the nuclei of tumour cells on the invasion front. Serial slides from the same tissue section. x 40

pRb in sinonasal lesions

comparable observations have been reported from animal models involving fetal mouse tissues (Szekely et al., 1992).

Sinonasal papillomas and adjacent respiratory epithelium were characterised by abundant pRb expression in all epithelial cell layers. Expression of pRb in proliferating cells in those lesions must be concluded. Changes in pRb function result from either deletion or mutation of the Retinoblastoma (Rb) gene on chromosome band 13q14.1-13q14.2, blocking of pRb by viral oncoproteins, or phosphorylation of pRb which is mediated by complexes comprised of a D-type cyclin and CDK4 and/or CDK6 (Greger et al., 1990; Goodrich et al., 1991; Dowdy et al., 1993; Pavelic et al., 1996; Caputi et al., 1998). Homozygous deletion of the Rb gene results in negative immunostaining for pRb whereas immunopositivity for pRb strongly correlates with functional Rb (Geradts et al., 1995). Hence, functional Rb in our specimens must be hypothesised. Recent studies revealed that oncoproteins of DNA viruses, including the E7 protein of human papillomavirus (HPV), form complexes with pRb involving the pocket region of pRb and a LXCXE motif of the partner protein resulting in dysregulation of pRb-mediated G1-checkpoint control (Dowdy et al., 1993). Interaction with the viral oncoprotein releases the pRb-imposed block on the activity of the positive transcription factors E2F. As a result the expression of several genes required for S-phase control, including c-myc, N-myc, and dihydrofolate reductase, is initiated (Nevins, 1992; Dowdy et al., 1993; Lee and Cho, 2002). An E7-dependent maintenance of cell proliferation conducive for viral replication is established (Nguyen et al., 2002). In addition, E7-mediated dysregulation of E2F proteins independently from pRb are currently proclaimed (Hwang et al., 2002). The development and progression of sinonasal inverted papillomas is strongly associated with HPV type 6/11 and 16/18 infection (Rady et al., 1998; Buchwald et al., 2001; Kraft et al., 2001). The presence of papillomavirus oncoprotein E7 in sinonasal papillomas has recently been demonstrated (Harris et al., 1998). However, reliable detection of oncoprotein E7 requires fresh tissue and thus was not carried out in our study on paraffin-embedded specimens. Further studies are necessary to clarify the relationship between oncoprotein E7 and pRb-mediated cell cycle control in sinonasal lesions. Inactivation of the growth suppressive function of pRb can be mediated through cyclin D-CDK4/CDK6 complexes leading to phosphorylation of pRb (Goodrich et al., 1991). The CDK-inhibitor p16 encoded by the CDKN2/ MTS1/ INK4 tumour suppressor gene negatively regulates the activity of these complexes thus preventing uncontrolled proliferation (Lukas et al., 1995; Fang et al., 1998). Loss of functional p16 by genomic or epigenetic alterations is associated with carcinogenesis in a variety of human tumours (Esteller et al., 2002), including carcinomas in the upper and lower airways (Kratzke et al., 1996; Caputi et al., 1998; Ambrosch et al., 2001; Baba et al.,

2001), the oesophagus (Roncalli et al., 1998; Mathew et al., 2001; Wong et al., 2001), the bladder (Benedict et al., 1999) as well as melanomas (Maelandsmo et al., 1996) and neuroblastomas (Omura-Minamisawa et al., 2001). In our study an abundant expression of p16 was revealed in normal respiratory epithelium as well as in cylindrical cell papillomas, columnar epithelium in inverted papillomas, and adjacent mucosa. Alterations of the CDKN2 gene result in a loss of p16 immunoreactivity (Benedict et al., 1999; El Naggar et al., 1999; Ambrosch et al., 2001). Hence, integrity of the CDKN2 gene and its transcription can be hypothesised from our immunohistochemical findings. However, additional molecular genetic studies are required to determine the status of the CDKN2 gene in sinonasal lesions. In surface cells of inverted papillomas, significantly reduced pRb expression corroborated with significantly increased p16 expression along with the stepwise metaplastic process from columnar respiratory epithelium to cuboidal epithelium and finally squamous metaplasia. Decreased transcription of the Rb gene due to p16 expression has repeatedly been evidenced (Lukas et al., 1995; Yeager et al., 1995; Fang et al., 1998; Ambrosch et al., 2001). As a result, reciprocal expression patterns of pRb and p16 are evident in immunohistochemistry (Pande et al., 1998; El Naggar et al., 1999). In sinonasal squamous cell carcinomas, however, we constantly observed the coexpression of pRb and p16. Dysbalances in the reciprocal expression of pRb and p16 in sinonasal carcinomas must be proclaimed. In invasive squamous cell carcinomas, overexpression of cyclin D1 was frequently observed. The cyclin D1 protein encoded by the Cyclin D1/ PRAD1/BCL-1/CCND1 gene on chromosome band 11q13 is expressed at the highest level in the middle and late G₁ phase of the cell cycle (Motokura et al., 1991; Bartkova et al., 1994; Müller et al., 1994). Overexpression of cyclin D1 resulting from cyclin D1 gene amplification or rearrangement is associated with loss of pRb-mediated growth suppression on the G₁ checkpoint of the cell cycle in several malignancies; for instance, in head and neck carcinomas (Bartkova et al., 1995; Papdimitrakopoulou et al., 2001; Akerval et al., 2002), lung cancer (Caputi et al., 1999; Jin et al., 2001), carcinomas of the upper and lower gastrointestinal tract (Roncalli et al., 1998; Jung et al., 2001; Nagasawa et al., 2001), the breast (Barbareschi et al., 1997; Hielsen et al., 1997), and the female genital tract (Rolfe et al., 2001). In accordance with previous studies, minimal levels of cyclin D1 immunopositivity indicate physiological expression (Bartkova et al., 1994). Overexpression of cyclin D1 can be assumed in specimens with more than 10% of immunoreactive cells (Roncalli et al., 1998). Carcinoma in situ as well as sinonasal papillomas and adjacent respiratory epithelium showed cyclin D1 expression only in a subset of cases and expression rates lower than 10% of cells were constantly observed. In all groups of benign sinonasal lesions no differences in pRb and p16 expression were found between cyclin D1-

positive specimens compared to cyclin D1-negative cases. Normal respiratory epithelium was constantly negative for cyclin D1 expression. Hence, an association between cyclin D1 overexpression and invasiveness of sinonasal squamous cell carcinomas can be postulated. Further studies involving larger cohorts and follow-up data are strongly required to determine the effect of cyclin D1 expression on sinonasal squamous cell carcinomas and its possible prognostic implications.

References

- Akervall J., Borg A., Dictor M., Jin C., Tanner M., Isola J., Mertens F. and Wennerberg J. (2002). Chromosomal translocations involving 11q13 contribute to cyclin D1 overexpression in squamous cell carcinoma of the head and neck. *Int. J. Oncol.* 20, 45-52.
- Ambrosch P., Schlott T., Hilmes D. and Ruschenburg I. (2001). p16 alterations and retinoblastoma protein expression in squamous cell carcinoma and neighbouring dysplasia from the upper aerodigestive tract. *Virchows Arch.* 438, 343-349.
- Baba Y., Tsukuda M., Mochimatsu I., Furukawa S., Kagata H., Satake K., Koshika S., Nakatani Y., Hara M., Kato Y. and Nagashima Y. (2001). Reduced expression of p16 and p27 proteins in nasopharyngeal carcinoma. *Cancer Detect. Prev.* 25, 414-419.
- Balogh K. (1997). Mouth, nose, and paranasal sinuses. In: *Histology for pathologists*. 2nd ed. Sternberg S. (ed). Lippincott-Raven. Philadelphia. pp 383-389.
- Barbareschi M., Pelosio P., Caffo O., Buttitta F., Pellegrini S., Barbazza R., Dalla Palma P., Bevilacqua G. and Marchetti A. (1997). Cyclin D-1-gene amplification and expression in breast carcinoma: Relation with clinicopathologic characteristics and with retinoblastoma gene product, p53 and p21^{WAF1} immunohistochemical expression. *Int. J. Cancer* 74, 171-174.
- Bartkova J., Lukas J., Strauss M. and Bartek J. (1994). Cell-cycle related variation and tissue-related expression of cyclin D1 protein. *J. Pathol.* 172, 237-245.
- Bartkova J., Lukas J., Müller H., Strauss M., Gusterson B. and Bartek J. (1995). Abnormal patterns of D-type cyclin expression and G1 regulation in human head and neck cancer. *Cancer Res.* 55, 949-959.
- Benedict W.F., Lerner S.P., Zhoe J., Shen X., Tokunaga H. and Czerniak B. (1999). Level of retinoblastoma protein expression correlates with p16 (MTS-1/INK4A/CDKN2) status in bladder cancer. *Oncogene* 18, 1197-1203.
- Buchwald C., Lindeberg H., Pedersen B.L. and Franzmann M.B. (2001). Human papilloma virus and p53 expression in carcinomas associated with sinonasal papillomas: A Danish epidemiological study 1980-1998. *Laryngoscope* 111, 1104-1110.
- Califano J., Koch W., Sidransky D. and Westra W.W. (2000). Inverted sinonasal papilloma: A molecular genetic appraisal of its putative status as a precursor to squamous cell carcinoma. *Am. J. Pathol.* 156, 333-337.
- Caputi M., Esposito V., Groeger A.M., De Luca A., Pacilio C., Dekan G., Giordano G.G., Baldi F., Wolner E. and Giordano A. (1998). RB growth control evasion in lung cancer. *Anticancer Res.* 18, 2371-2374.
- Caputi M., Groeger A.M., Esposito V., Dean C., De Luca A., Pacilio C., Muller M.R., Giordano G.G., Baldi F., Wolner E. and Giordano A. (1999). Prognostic role of cyclin D1 in lung cancer. Relationship to proliferating cell nuclear antigen. *Am. J. Respir. Cell. Mol. Biol.* 20, 746-750.
- Dowdy S.F., Hinds P.W., Loule K., Reed S.I., Arnold A. and Weinberg R.A. (1993). Physical interaction of the retinoblastoma protein with human D cyclins. *Cell* 73, 499-511.
- El-Naggar A.K., Lai S., Clayman G.L., Zhou J.H., Tucker S.A., Myers J., Luna M.A. and Benedict W.F. (1999). Expression of p16, Rb, and cyclin D1 gene products in oral and laryngeal squamous carcinoma: Biological and clinical implications. *Hum. Pathol.* 30, 1013-1018.
- Esteller M. and Herman J.G. (2002). Cancer as an epigenetic disease: DNA methylation and chromatin alterations in human tumours. *J. Pathol.* 196, 1-7.
- Fang X., Jin X., Xu H.J., Liu L., Peng H.Q., Hogg D., Roth J.A., Yu O., Xu F., Best R.C. and Mills G.B. (1998). Expression of p16 induces transcriptional downregulation of the RB gene. *Oncogene* 16, 1-8.
- Gerardts J., Kratzke R.A., Niehans G.A. and Lincoln C.E. (1995). Immunohistochemical detection of the cyclin-dependent kinase inhibitor 2/ multiple tumour suppressor gene 1 (CDKN2/ MTS1) product p16INK4A in archival human solid tumours. Correlation with retinoblastoma protein expression. *Cancer Res.* 55, 6006-6011.
- Goodrich D.W., Wang N.P., Qian Y.W., Lee E.Y. and Lee W.H. (1991). The retinoblastoma gene product regulates progression through the G1 phase of the cell cycle. *Cell* 67, 293-302.
- Greger V., Schirmacher P., Bohl J., Bornemann A., Hurter T., Passarge E. and Horsthemke B. (1990). Possible involvement of the retinoblastoma gene in undifferentiated sinonasal carcinoma. *Cancer* 66, 1954-1959.
- Guichard C., Gilain L., Al Samad I.A., Piron G., Brugel L., Escudier E. and Coste A. (1998). Epithelial cell proliferation, apoptosis, and apoptosis inhibition in inverted papillomas. *Laryngoscope* 108, 716-720.
- Harris M.O., Beck J.C., Lancaster W., Gregoire L., Carey T.E. and Bradford C.R. (1998). The HPV 6 E6/E7 transforming genes are expressed in inverted papilloma. *Otolaryngol. Head Neck Surg.* 118, 312-318.
- Hielsen N.H., Emdin S.O., Cajander J. and Landberg G. (1997). Deregulation of cyclin E and cyclin D1 in breast cancer is associated with inactivation of the retinoblastoma protein. *Oncogene* 14, 295-304.
- Hwang S.G., Lee D., Kim J., Seo T. and Choe J. (2002). Human papillomavirus type 16 E7 binds to E2F1 and activates E2F1-driven transcription in a retinoblastoma protein-independent manner. *J. Biol. Chem.* 277, 2923-2930.
- Jardine A.H., Davies G.R. and Birchall M.A. (2000). Recurrence and malignant degeneration of 89 cases of inverted papilloma diagnosed in a non-tertiary referral population between 1975 and 1995: Clinical predictors and p53 studies. *Clin. Otolaryngol.* 25, 363-369.
- Jin M., Inoue S., Umemura T., Moriya J., Arakawa M., Nagashima K. and Kato H. (2001). Cyclin D1, p16 and retinoblastoma gene product expression as a predictor for prognosis in non-small cell lung cancer at stages I and II. *Lung Cancer* 34, 207-218.
- Jung A., Schrauder M., Oswald U., Knoll C., Sellberg P., Palmquist R., Niedobitek G., Brabletz T. and Kirchner T. (2001). The invasion front of human colorectal adenocarcinomas shows co-localisation of nuclear beta-catenin, cyclin D(1), and p16(INK4A) and is a region of low proliferation. *Am. J. Pathol.* 159, 1613-1617.
- Klimek T., Atai E., Schubert M. and Glanz H. (2000). Inverted papilloma of the nasal cavity and paranasal sinuses: Clinical data, surgical strategy and recurrence rates. *Acta Otolaryngol.* 120, 267-272.

pRb in sinonasal lesions

- Kraft M., Simmen D., Casas R. and Pfaltz M. (2001). Significance of human papillomavirus in sinonasal papillomas. *J. Laryngol. Otol.* 115, 709-714.
- Kratzke R.A., Greatens T.M., Rubins J.B., Maddaus M.A., Niewoehner D.E., Niehans G.A. and Geradts J. (1996). Rb and p16INK4a expression in resected non-small cell lung tumours. *Cancer Res.* 56, 3415-3420.
- Lawson W., Ho B., Shaari C.M. and Biller H.F. (1995). Inverted papilloma: A report of 112 cases. *Laryngoscope* 105, 282-288.
- Lee C., Cho Y. (2002). Interactions of SV40 large T antigen and other viral proteins with retinoblastoma tumour suppressor. *Rev. Med. Virol.* 12, 81-92.
- Lukas J., Parry D., Aagaard L., Mann D.J., Bartkova J., Strauss M., Peters G. and Bartek J. (1995). Retinoblastoma-protein-dependent cell-cycle inhibition by the tumour suppressor p16. *Nature* 375, 503-506.
- Maelandsmo G.M., Florenes V.A., Hovig E., Oyjord T., Engebraaten O., Holm R., Borresen A.L. and Fodstad O. (1996). Involvement of the pRb/ p16/ cdk4/ cyclin D1 pathway in the tumorigenesis of sporadic malignant melanomas. *Br. J. Cancer* 73, 909-916.
- Mathew R., Arora S., Mathur M., Chattopadhyay T.K. and Ralhan R. (2001). Esophageal squamous cell carcinomas with DNA replication errors (RER+) are associated with p16/ pRb loss and wild-type p53. *J. Clin. Cancer Res. Clin. Oncol.* 127, 603-612.
- Michaels L. and Young M. (1995). Histogenesis of papillomas of the nose and paranasal sinuses. *Arch. Pathol. Lab. Med.* 119, 821-826.
- Motokura T., Bloom T., Kim H.G., Juppner H., Ruderman J.V., Kronenberg H.M. and Arnold A. (1991). A novel cyclin encoded by a bcl1-linked candidate oncogene. *Nature* 350, 512-518.
- Müller H., Lukas J., Schneider A., Warthoe P., Bartek J., Eilers M. and Strauss M. (1994). Cyclin D1 expression is regulated by the retinoblastoma protein. *Proc. Natl. Acad. Sci. USA* 91, 2945-2949.
- Nagasawa S., Onda M., Sasajima K., Makino H., Yamashita K., Tabuko K. and Miyashita M. (2001). Cyclin D1 overexpression as a prognostic factor in patients with esophageal carcinoma. *J. Surg. Oncol.* 78, 208-214.
- Nevins J.R. (1992). E2F: a link between the Rb tumor suppressor protein and viral oncoproteins. *Science* 258, 424-429.
- Nguyen D.X., Westbrook T.F. and McCance D.J. (2002). Human papillomavirus type 16 E7 maintains elevated levels of cdc25A tyrosine phosphatase during deregulation of cell cycle arrest. *J. Virol.* 76, 619-632.
- Omura-Minamisawa M., Diccianni M.B., Chang R.C., Batova A., Bridgeman L.J., Schiff J., Cohn S.L., London W.B. and Yu A.L. (2001). P16/ p14(ARF) cell cycle regulatory pathways in primary neuroblastoma: p16 expression is associated with advanced stage disease. *Clin. Cancer Res.* 11, 3481-3490.
- Pande P., Mathur M., Shukla N.K., Ralhan R. (1998). pRb and p16 protein alterations in human oral tumorigenesis. *Oral Oncol.* 34, 396-403.
- Papadimitrakopoulou V.A., Izzo J., Mao L., Keck J., Hamilton D., Shin D.M., El-Naggar A., den Hollander P., Liu D., Hittelman W.N. and Hong W.K. (2001). Cyclin D1 and p16 alterations in advanced premalignant lesions of the upper aerodigestive tract: Role in response to chemoprevention and cancer development. *Clin. Cancer Res.* 7, 3127-3134.
- Pavelic Z.P., Lasmar M., Pavelic L.J., Sorensen C., Stambrook P.J., Zimmermann N. and Gluckman J.L. (1996). Absence of retinoblastoma gene product in human primary oral cavity carcinomas. *Oral Oncol., Eur. J. Cancer* 32B, 347-351.
- Rady P.L., Schnadig V.J., Weiss R.L., Hughes T.K. and Tyring S.K. (1998). Malignant transformation of recurrent respiratory papillomatosis associated with integrated human papillomavirus type 11 DNA and mutation of p53. *Laryngoscope* 108, 735-740.
- Ramm B. and Hofmann G. (1982). *Biomathematik. Enke. Stuttgart.* pp 176-179.
- Rolfe K.J., Crow J.C., Benjamin E., Reid W.M., MacLean A.B. and Perrett C.W. (2001). Cyclin D1 and retinoblastoma protein in vulvar cancer and adjacent lesions. *Int. J. Gynecol. Cancer* 11, 381-386.
- Roncalli M., Bosari S., Manchetti A., Buttitta F., Bossi P., Graziani D., Peracchia A., Bonavina L., Viale G. and Coggi G. (1998). Cell cycle-related gene abnormalities and product expression in esophageal carcinoma. *Lab. Invest.* 78, 1049-1057.
- Schwerer M.J., Kraft K., Baczako K. and Maier H. (2001). Coexpression of cytokeratins typical for columnar and squamous differentiation in sinonasal inverted papillomas. *Am. J. Clin. Pathol.* 115, 474-754.
- Shanmugaratnam K. and Sobin L.H. (1991). *Histological typing of tumours of the upper respiratory tract and ear.* 2nd ed. Springer. Berlin. pp 20-21.
- Szekely L., Jiang W.Q., Bulic-Jakus F., Rosen A., Ringertz N., Klein G. and Wiman K.G. (1992). Cell type and differentiation dependent heterogeneity in retinoblastoma protein expression in SCID mouse fetuses. *Cell Growth Differ.* 3, 149-156.
- Thorp M.A., Oyarzabal-Amigo M.F., du Plessis J.H. and Sellars S.L. (2001). Inverted papilloma: A review of 53 cases. *Laryngoscope* 111, 1401-1405.
- Wong D.J., Paulson T.G., Prevo L.J., Galipeau P.C., Longton G., Blount P.L. and Reid B.J. (2001). p16(INK4a) lesions are common, early abnormalities that undergo clonal expansion in Barrett's metaplastic epithelium. *Cancer Res.* 61, 8284-8289.
- Yeager T., Stadler W., Belair C., Puthenveettil J., Olopade O. and Reznikoff C. (1995). Increased p16 levels correlate with pRb alterations in human urothelial cells. *Cancer Res.* 55, 493-497.