

The usefulness of p16 and COX-2 expression on the prediction of progression to endometrial cancer

Hande Ece Kalkan^{1*}, Levent Akman^{2*}, Gurdeniz Serin³,
Mustafa Cosan Terek², Osman Zekioglu³ and Ahmet Aydin Ozsaran²

¹Department of Obstetrics and Gynecology, Private Nefes Hospital, Kastamonu, ²Department of Obstetrics and Gynecology, Oncology Division and ³Department of Pathology, Ege University Medical School, Izmir, Turkey

*Hande Ece Kalkan and Levent Akman are equal contributors to this work and designated as co-first authors

Summary. Objectives. Endometrial cancer (EC) is the most commonly diagnosed gynecological cancer. Endometrial hyperplasia (EH) is a more common diagnosis than EC. Endometrial hyperplasia is found in approximately 1.5% of all women presenting with abnormal bleeding. Endometrial hyperplasia progresses to EC, and especially, cancer risk increases in cases with atypical hyperplasia. p16, one of the tumor suppressor proteins involved in the cell cycle, and COX-2, one of the key enzymes of prostaglandin synthesis, are important markers for the diagnosis of both EH and EC. There is lack of consensus in the classification, diagnosis and treatment of EH. The subject of changes in the cell cycle in the progression of endometrial pathologies may help to identify and prevent these affected pathways in the treatment stage. The aim of this study is to investigate the expression of p16 and COX-2 during the development of EC from EH.

Material and methods. We investigated COX-2 and P16 expressions in patients with proliferative endometrium, complex/simple endometrial hyperplasia and endometrioid adenocarcinoma.

Results. p16 expression increased in EH and EC ($p < 0.001$). COX-2 expression was increased in endometrial cancer compared to other groups, but this increase was not found to be statistically significant. Although p16 and COX-2 expression were increased in patients with advanced grade/stage, lymphovascular invasion, and >50% of myometrial invasion, this increase was not statistically significant.

Conclusions. More detailed studies are needed to investigate the prognostic significance of the COX-2 molecule. COX-2 might be a potential biomarker for the prognosis of endometrial cancer and a potential therapeutic target for EC treatment. Also, it might be

used to prevent the progression of precursor lesions to invasive EC.

Key words: Cyclooxygenase-2 (COX-2), Endometrial cancer, Endometrial hyperplasia, P16

Introduction

Endometrial cancer ranks fourth in women after lung, breast, and bowel cancer and accounts for about half of all gynecological cancers (Greenlee et al., 2000; Braun et al., 2016). Demographic data shows that 1-3% of all women will face the risk of endometrial cancer at some point in their lives. Approximately 20% of these patients are lost due to the disease within 5 years, although most known treatment methods are applied. The increasing frequency of endometrial cancer has led to serious research to find the most effective treatment methods.

The incidence of endometrial hyperplasia (EH) (133 per 100,000 women per year) is estimated to be at least three times higher than endometrial cancer (Reed et al., 2009). Endometrial hyperplasia is found in approximately 1.5% of all women presenting with abnormal bleeding. Different classifications have been defined for EHs. In the classification made by the World Health Organization (WHO), endometrial hyperplasia is divided into 4 subgroups using cellular atypia and structural patterns of glands (Baak et al., 2005; Steinbakk et al., 2011). Although this classification is widely used worldwide, it shows high intra and inter-observer variations in the evaluation of the most important prognostic factor, cellular atypia, and its reproducibility is low.

Another classification, endometrial intraepithelial neoplastic (EIN) system, is a classification developed to better manage patient treatment (Steinbakk et al., 2011). According to WHO, 63% of patients diagnosed with EIN had atypical endometrial hyperplasia, 27% complex

Corresponding Author: Levent Akman, MD, Ege University Medical School, Department of Obstetrics and Gynecology, 35100, Bornova, Izmir-Turkey. e-mail: leventakman@gmail.com
www.hh.um.es. DOI: 10.14670/HH-18-650



endometrial hyperplasia and 10% simple endometrial hyperplasia. Likewise, EIN was detected in 79% of patients diagnosed with atypical endometrial hyperplasia, 44% of patients with complex endometrial hyperplasia and only 5% of patients with simple endometrial hyperplasia. Studies have shown that there is no compatibility between the two systems. The use of immune histochemical markers are proposed due to the incompatibility between existing classification systems and their inability to predict disease progression. p16 and COX-2 are important markers for the diagnosis of both EH and cancer (Lambropoulou et al., 2005; Steinbakk et al., 2011). COX-2 is expressed in the cytoplasm of normal proliferative glandular epithelium and endometrial cancer cells (Uotila et al., 2002). COX-2 plays an important role both in protecting the endometrium during the menstrual cycle and in endometrial carcinogenesis (Jarzabek et al., 2013). COX-2 positivity is generally an indication for poor prognosis, as it increases the production of prostaglandin in neoplasms. COX-2 expression increases in endometrial carcinoma compared to hyperplasia (Steinbakk et al., 2011). COX-2 expression is increased while progressing to EH and cancer. In some studies, it has been stated that in patients with cancer, COX-2 expression decreases (Greenlee et al., 2000; Faloppa et al., 2014).

The aim of this study is to investigate the expression of p16 and COX-2 during the development of EC from EH. Therefore, in our study, we investigated COX-2 and p16 expressions in patients with proliferative endometrium, complex/simple endometrial hyperplasia and endometrioid adenocarcinoma. There is a lack of consensus in the classification, diagnosis and treatment of EH. The subject of changes in the cell cycle in the progression of endometrial pathologies will help to identify and prevent these affected pathways in the treatment stage.

Materials and methods

Approval of Institutional ethics Committee of the Medical University of Ege, no. 15-11.1/15 has been obtained for this study. Patients included in the study were randomly selected by retrospective scanning of patient files who applied to the Ege University Obstetrics and Gynecology Clinic between 2012 and 2016. The patients underwent endometrial sampling for various reasons and were operated for endometrial cancer.

Study group

The groups in the study are designed as follows:

1-Control group: Women over 30 years of age without any gynecological malignancy with proliferative endometrium diagnosed by endometrial biopsy (n: 30)

2-Women over 30 years of age without any gynecological malignancy detected with simple non-atypical endometrial hyperplasia diagnosed by

endometrial biopsy (n: 30)

3-Women over 30 years of age without any gynecological malignancy with endometrial hyperplasia with complex atypia diagnosed by endometrial biopsy (n: 30)

4-Patients with endometrioid type adenocarcinoma diagnosed by final pathology after hysterectomy (n: 30).

Immunohistochemistry

Pathology preparations of all patients were reassessed and p16 (INK4a) (Clone E6H4, Dako Cytomation, Glostrup, Denmark; dilution at 1:100) and COX-2 (Clone CX294, Dako Cytomation, Glostrup, Denmark; dilution at 1:100) expressions were examined in endometrial tissue samples. Two pieces of 5-micron thickness series were used for studying p16 (INK4a) and COX-2 from the formalin-fixed paraffin-embedded tissue blocks in the pathology archive of the cases. Sections were taken on the positively charged slides.

A fully automatic immunohistochemistry staining device (BenchMark XT, Ventana medical systems, Tuscon, AZ) with biotin-free, HRP multiplier-based hydrogen peroxide substrate and 3,3-diaminobenzidine tetrahydrochloride chromogen ready kit (ultra-view Universal DAB Detection Kit, catalog number 760-500 for immunohistochemically staining BenchMark XT, Ventana Medical Systems, Tuscon, AZ) was used. Standard boiling was applied for 60 minutes. Tissue specimens were dried at room temperature for at least 3 hours and antigen release was performed on the BenchMark XT fully automated immunohistochemistry staining device. Primary antibodies were incubated at 37°C for 32 minutes. The dehydration of the sections, whose negative control was completed with hematoxylin and bluing solution in the device, was done automatically with xylene, and the coverslip closure was performed automatically (Dako CoverStainer, CS 100-10073, Agilent Technologies, Santa Clara, CA, USA).

Quantification of Immunohistochemistry

The interpretation criteria for p16 (INK4a) and COX-2 (clone; CX-294) were used for the evaluation of the immunohistochemical staining of pathological sections.

p16 (INK4a): Nuclear and cytoplasmic staining were accepted as positive. Cases without staining were considered negative. The percentage of positive tumor cells was evaluated as, <5%=1(+), 5-50%=2(+), >50%=3(+).

COX-2: The preparations were evaluated in terms of staining intensity and percentage of positive tumor cells. Staining intensity was accepted as 0=negative, 1=weak, 2=moderate, 3=strong. The percentage of positive tumor cells; if there was no staining, it was evaluated as 0, 1-25%=1, 25-50%=2, >50%=3. Overall scores were assessed by the sum of percentage of positive cells and

Expression of P16 and COX-2 in endometrial cancer

intensity of expression, being evaluated as follows: 0=no staining, 1=2-3 with total score, 2=4-5 with total score, 3=6 with total score.

Statistical analysis

The statistical evaluation of the study was done with the help of SPSS 16.0 ready package program. The variables of the groups, normality, and homogeneity of variances were evaluated after the preconditions were checked. The data were given as median (minimum-maximum) since the data in the groups were not distributed normally and categorical variables and non-parametric tests were used in the comparative data between the groups for the same reason. Kruskal Wallis test was used to compare continuous variables between groups, and Mann Whitney U test for post hoc analysis. Chi-square test was used to compare categorical variables in groups. When a difference was found between the groups, it was tried to reveal the clinical, demographic and laboratory variables that may have an effect on this difference with univariate or multivariate regression analysis. P-value <0.05 was considered significant.

Results

The descriptive and clinical characteristics (age, body mass index (BMI), history of smoking, CA125 level, endometrial thickness, parity) of the patients are shown in Table 1. When EC group (Group 4) was compared with other groups, age, BMI, CA-125 levels and endometrial thickness were statistically significantly high ($p<0.05$).

COX-2 and p16 staining scores are shown in Figure 1 and 2. In terms of group 1 to 4, COX-2 and p16 surface staining scores, both had positive correlations and the scores for groups increased from 1 to 4 for both. P16 expression was statistically significantly different among the groups ($p<0.001$). COX-2 staining total scores were higher in the complex atypical hyperplasia and endometrial carcinoma group compared with other groups, but this increase was not statistically significant. However, when COX-2 immunohistochemical staining total score was evaluated as weak (total score 1 and 2) and strong (total score 3) staining between groups, strong staining towards endometrial cancer was statistically significant ($p=0.006$).

In the group with endometrial carcinoma, the depth

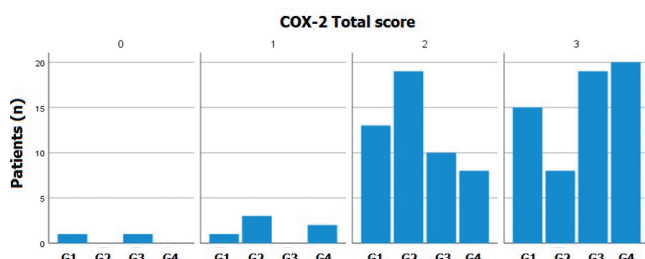


Fig. 1. COX-2 staining scores among the groups. The scores, assessed by the sum of percentage of positive cells (using the marks: 0=no staining, 1=1-25%, 2=25-50%, 3≥50%) and intensity of expression (0=negative, 1=weak, 2=moderate and 3=strong), were evaluated as 0=no staining, 1=2-3 with total score, 2=4-5 with total score, 3=6 with total score. COX-2, cyclooxygenase-2; Group 1, Proliferative endometrium; Group 2, Simple non-atypical endometrial hyperplasia; Group 3, Complex atypical endometrial hyperplasia; Group 4, Endometrial carcinoma.

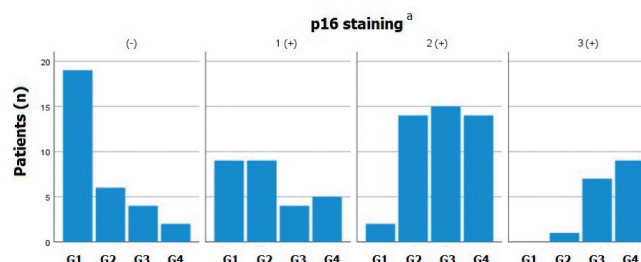


Fig. 2. p16 staining among the groups. The preparations were evaluated in terms of percentage of positive tumor cells. It was evaluated as negative=no staining, 1(+) ≤5%, 2(+) =5-50%, 3(+) >50%. Group 1, Proliferative endometrium; Group 2, Simple non-atypical endometrial hyperplasia; Group 3, Complex atypical endometrial hyperplasia; Group 4, Endometrial carcinoma.

^a: $p<0.001$, between the four groups.

Table 1. The descriptive and clinical characteristics (age, body mass index (BMI), history of smoking, CA125 level, endometrial thickness, parity) of the patients among the groups.

	Group-1 Proliferative endometrium (n=30)	Group-2 Simple non-atypical endometrial hyperplasia (n=30)	Group-3 Complex atypical endometrial hyperplasia (n=30)	Group-4 Endometrial carcinoma (n=30)
Age (years) Median (min-max)	42 (30-57)	45 (31-57)	50 (37-65) ^a	60,5 (39-74) ^{a,b,c}
Parity Median (min-max)	2 (0-3)	2 (0-5)	2 (0-5)	2 (0-4)
Smoking; n (%)	10 (33,3)	12 (40)	6 (20)	2 (6,7)
BMI (kg/m ²) Median (min-max)	28,5 (20-39)	30 (20-48)	32 (22-42) ^a	34 (26-57) ^{a,b}
Ca125 (U/ml) Median (min-max)	8 (1-19)	13 (1-420) ^a	15 (5-30) ^a	23,5 (6-1005) ^a
Endometrial thickness(mm) Median (min-max)	9 (2-17)	12 (3-23)	10 (6-20)	13,5 (5-29) ^a

^a: $p<0.05$ vs. Group 1, ^b: $p<0.001$ vs. Group 2, ^c: $p<0.05$ vs. Group 3.

Expression of P16 and COX-2 in endometrial cancer

Table 2. The prognostic characteristics and p16 / COX-2 staining scores in endometrial carcinoma patients.

Endometrial Carcinoma (n=30)	p16 positive (n, %)	COX-2 (total score 3) Strong (n, %)	COX-2 (total score 1 and 2) Weak (n, %)
Stage 1a (n=19)	18 (94,7)	13 (68,4)	6 (31,6)
Stage 1b (n=8)	7 (87,5)	4 (50)	4 (50)
Stage 2 (n=3)	3 (100)	3 (100)	0
Grade 1 (n=6)	6 (100)	5 (83,3)	1 (16,7)
Grade 2 (n=22)	20 (90,9)	13 (59,1)	9 (40,9)
Grade 3 (n=2)	2 (100)	2 (100)	0
Lymphovascular invasion Negative (n=24)	22 (91,2)	15 (62,5)	9 (37,5)
Lymphovascular invasion Positive (n=6)	6 (%100)	5 (83,3)	1 (17,7)
Myometrial invasion >%50 (n=11)	11 (%100)	8 (72,7)	3 (27,3)
Myometrial invasion ≤%50 (n=19)	17 (89,5)	12 (63,2)	7 (36,8)

of myometrial invasion, tumor size, lymphovascular invasion, cervical involvement, stage and tumor grades were evaluated. All of the patients included in the endometrial carcinoma group are endometrioid type adenocarcinoma, and the FIGO grading system was used for histological grading. The prognostic characteristics and p16/COX-2 staining scores in endometrial carcinoma patients are shown in Table 2. Stage III and IV cases were not observed.

A high rate of p16 expression and COX-2 strong expression were detected in all patients in G3 and Stage 2 endometrial cancer. Also, both expressions increased in patients with lymphovascular invasion and >50% of myometrial invasion. However, p16 expression and COX-2 strong expression did not have a statistically significant relationship with prognostic factors such as tumor stage, grade, lymphovascular invasion and depth of myometrial invasion.

Discussion

Cyclooxygenase-2 plays a role in the conversion of arachidonic acid in the cell membrane to prostaglandin H₂ and E₂. PGE₂ has many functions such as cell proliferation, differentiation, and apoptosis. Therefore, COX-2 may function as an effective prognostic biomarker and a potential therapeutic target for endometrial cancer. COX-2 expression was found in most colorectal adenocarcinoma patients. In an *in vitro* study, COX-2 downregulation significantly inhibited the growth and invasiveness of the endometrial adenocarcinoma cell line HEC-1B (Xiao et al., 2015). Also, COX-2 has increased expression in endometrial carcinoma compared to normal endometrium (Comerci et al., 2000; Einstein et al., 2000; Tong et al., 2000). Erkanli et al. showed that in endometrial hyperplasia and endometrial carcinoma, COX-2 was found to be overexpressed compared to the normal endometrium (p=0.02) (Erkanli et al., 2007). Nasir et al., in a retrospective study showed a high COX-2 positivity rate in human endometrial carcinoma tissues (88%) as compared to endometrial hyperplasia, atypical complex hyperplasia and non-neoplastic endometrial tissues. They suggest that expression of COX-2 might well be

the "signal" of cancerous transformation in these cells and COX-2 inhibitors may play an important role in the clinical management of endometrial cancer (Nasir et al., 2007). In our study, it was found that the expression of COX-2 is increased in the complex atypical hyperplasia and endometrial carcinoma group, but this increase was not statistically significant. However, when COX-2 immunohistochemical staining total score was evaluated as weak (total score 1 and 2) and strong (total score 3) staining between groups, strong staining towards endometrial cancer was statistically significant (p=0.006).

The prognostic significance of COX-2 expression in endometrial carcinoma is controversial. Oplawski et al. investigated COX-2 expression in different grades of endometrial cancer (Oplawski et al., 2020). In their study, analysis of COX-2 expression showed that the optical density of the reaction product in G1 reached 186% in the control group, 243% in the G2 and 293% in the G3 group. These results suggest that changes in the expression of COX-2 may be potentially useful in predicting the progression of endometrial cancer and treatment effectiveness. Also, Cao et al. noted the overexpression of COX-2 in poorly differentiated form of endometrial cancer, while not observing its expression in a well-differentiated form. They indicated the key role of COX-2 in the progression of endometrial cancer (Cao et al., 2002). Ferrandina et al. reported that the frequency of COX-2 overexpression in late FIGO stage patients was higher than that in patients with <50% myometrial invasion (Ferrandina et al., 2002). However, Erkanli et al. could not demonstrate any association between COX-2 overexpression and endometrium cancer prognostic factors (myometrial invasion, grade, stage) (Erkanli et al., 2007). COX-2 overexpression does not affect survival and is not a prognostic factor in cancer development. In a retrospective study by Orejuela et al. no statistically significant difference was found between tumor stage and grade and COX-2 expressions in endometrial carcinoma (Orejuela et al., 2005). In a study by Li et al. they detected COX-2 down regulation in a large series of endometrioid tumors and concluded that COX-2 expression is not a significant prognostic factor in tumor development (Li et al., 2002). Also, in the study

Expression of P16 and COX-2 in endometrial cancer

of Faloppa et al. they conclude that COX-2 expression is lower in EC compared with nonmalignant endometrial lesions (benign endometrial polyps, endometrial hyperplasia, endometrial intraepithelial neoplasia) and COX-2 expression has no prognostic value in EC (Faloppa et al., 2014). In a recent meta-analysis, Li et al. investigated the role of COX-2 in the determination of the risk, prognosis, and clinical features of endometrial cancer. Their results suggested that COX-2 overexpression is significantly associated with poor prognosis and advanced clinical features in endometrial cancer (Li et al., 2020). In our study, a high rate of COX-2 expression was detected in all patients in G3 and advanced stages in endometrial cancer. However, COX-2 expression did not have a statistically significant relationship with prognostic factors such as tumor stage, grade, lymphovascular invasion and depth of myometrial invasion. The low number of advanced stage and G3 patients in endometrial cancer group may have affected these statistical results.

Many studies show that PG receptors are associated with endometrial carcinoma carcinogenesis (Sales et al., 2004; Battersby et al., 2007; Zhu et al., 2018; Ye et al., 2020; Lyndin et al., 2022). Ye et al. emphasized that further investigations concerning PG receptors in gynecological cancers are necessary. They may represent novel and specific anti-inflammation targets for gynecological cancer chemoprevention and combination with COX2 enzyme inhibitors might provide more advantages (Ye et al., 2020). Also, Kosmas et al determined the expression of cyclooxygenase-2 (COX-2) in endometrial adenocarcinoma in imprint smears as an alternative technique and to correlate the results with clinicopathologic parameters. They showed that positive expression of COX-2 in malignant cells was related to morphological features of more aggressive tumors (pathogenetic type II, advanced clinical stage, mainly high grade, deep myometrial involvement >1/2) and more lymph node involvement (41.2% vs 13.4%) (Kosmas et al., 2020).

In recent years multiomic studies have provided extremely important and detailed information on topics related to the molecular basis of cancer, potential molecular markers, and therapeutic targets. Multiomics data include genome, transcriptome, proteome, metabolome, and epigenome data. These approaches have also been applied in endometrial cancer research in order to identify novel molecular markers and therapeutic targets. Boron et al. reviewed recent multiomic approaches in endometrial cancer and this review provided some important findings (Boron et al., 2022). Among these studies, Zou et al. investigated the expression of leucine-rich repeat-containing G protein coupled receptor 5 (LGR5), somatostatin (SST), prostaglandin D2 synthase (PTGDS), and zinc finger protein 558 (ZNF558) in endometrial cancer (Zou et al., 2020). They have reported that the expression of all four genes was associated with EC prognosis. More validation demonstrated that PTGDS was significantly

downregulated in the EC group compared with the atypical hyperplasia and normal endometrial groups, and its low expression was an independent risk factor for worse prognosis of EC. They concluded that LGR5, SST, ZNF558, and PTGDS may participate in the development, progression, and prognosis of EC, in which PTGDS may be a novel biomarker and therapeutic target for EC.

p16 is one of the tumor suppressor genes known to have anti-proliferative effects in tumor development. Studies report that p16 expression increases in advanced age, oxidative stress and DNA damage (Ressler et al., 2006; Horr e et al., 2007; Fordyce et al., 2010). Increased expressions of p16 have been reported in the literature in endometrial cancer (Sood et al., 1997). Although it is known to be a critical tumor suppressor protein in the cancer development process, increased expression in some cancers has also been reported due to reasons not fully understood. The reason for this increase is thought to be a protective mechanism to stop cell proliferation, which has increased secondary to the inactivation of the Rb (retinoblastoma) protein (Reuschenbach et al., 2008). Yoon et al evaluated to stromal p16 expression in benign, precancerous, and malignant endometrial lesions using immunohistochemistry. They showed that atypical hyperplasia/endometrial intraepithelial neoplasia and serous endometrial intraepithelial carcinoma had significantly higher stromal p16 expression levels than benign lesions. In addition, endometrioid carcinoma, serous carcinoma, and carcinosarcoma showed significantly elevated stromal p16 expression levels compared with benign and precancerous lesions. However, differences in stromal p16 expression among nonpathological endometrium, atrophic endometrium, endometrial polyp, and hyperplasia without atypia were not statistically significant (Yoon et al., 2017). Our observations support this situation. The degree of p16 staining increases with hyperplasia and carcinoma from the normal endometrium. In the complex endometrial hyperplasia and endometrial carcinoma group, 3(+) positive staining rates were found to be increased compared to other groups. There was no 3(+) staining in the proliferative endometrium group, and only one patient had 3(+) staining in the simple atypical endometrial hyperplasia group.

In conclusion; we found that p16 expression increased in endometrial hyperplasia and endometrial cancer. Although there was no increase in correlation with other endometrial cancer prognostic factors, especially in patients with endometrial cancer, their expressions were found to be significantly higher compared to other groups. p16 expression promotes the development and progression of endometrial cancer and is association with worse oncogenic behavior. Although increased expression of the COX-2 molecule in endometrial cancer has been reported in the literature, there is no consensus about the effect on the stages of carcinogenesis. In our study, COX-2 expression was

increased in endometrial cancer compared to other groups, but this increase was not found to be statistically significant. However, when COX-2 immunohistochemical staining total score was evaluated as weak (total score 1 and 2) and strong (total score 3) staining between groups, strong staining towards endometrial cancer was statistically significant ($p=0.006$). Also, a high rate of COX-2 expression was detected in all patients in G3 and advanced stages in endometrial cancer. However, COX-2 expression did not have a statistically significant relationship with prognostic factors such as tumor stage, grade, lymphovascular invasion and depth of myometrial invasion.

There were some limitations in this study. There were a limited number of patients in our study. In the endometrial cancer group, the low number of patients, especially in G3 and advanced stages, may have affected the statistical significance in the evaluation of prognostic factors. These results emphasize the importance of conducting larger-scale studies in the future. More detailed studies are needed to investigate the prognostic significance of the COX-2 molecule and the mechanisms by which it plays a role in carcinogenesis. COX-2 might be a potential biomarker for the prognosis of endometrial cancer and a potential therapeutic target for EC treatment. Also, it might be used to prevent the progression of precursor lesions to invasive EC.

Competing interests. All authors have no conflicts of interest to disclose.

References

- Baak J.P., Mutter G.L., Robboy S., van Diest P.J., Uytendaele A.M., Orbo A., Palazzo J., Fiane B., Lovslett K., Burger C., Voorhorst F. and Verheijen R.H. (2005). The molecular genetics and morphometry-based endometrial intraepithelial neoplasia classification system predicts disease progression in endometrial hyperplasia more accurately than the 1994 World Health Organization classification system. *Cancer* 103, 2304-2312.
- Battersby S., Sales K.J., Williams A.R., Anderson R.A., Gardner S. and Jabbour H.N. (2007). Seminal plasma and prostaglandin E2 up-regulate fibroblast growth factor 2 expression in endometrial adenocarcinoma cells via E-series prostanoid-2 receptor-mediated transactivation of the epidermal growth factor receptor and extracellular signal-regulated kinase pathway. *Hum. Reprod.* 22, 36-44.
- Boroń D., Zmarzły N., Wierzbik-Strońska M., Rosińczuk J., Mieszczarski P. and Grabarek B.O. (2022). Recent multiomics approaches in endometrial cancer. *Int. J. Mol. Sci.* 23, 1237.
- Braun M.M., Overbeek-Wager E.A. and Grumbo R.J. (2016) Diagnosis and management of endometrial cancer. *Am. Fam. Physician.* 93, 468-474.
- Cao Q.J., Einstein M.H., Anderson P.S., Runowicz C.D., Balan R. and Jones J.G. (2002). Expression of COX-2, Ki-67, cyclin D1, and P21 in endometrial endometrioid carcinomas. *Int. J. Gynecol. Pathol.* 21, 147-154.
- Comerci J.T., Sloan C., Edwards R.P., Makhia S.K., Krohn M. and Hatem F. (2000). Cyclooxygenase-2 expression in normal endometrium, endometrial hyperplasia, and carcinoma. Proceedings of the 32nd Annual Meeting of the Society of Gynecologic Oncology, Nashville, Tennessee. Abstract 108.
- Einstein M.H., Cao Q.J. and Weiss H. (2000). Expression of cyclooxygenase in endometrial cancer *in vivo*. Proceedings of the 32nd Annual Meeting of the Society of Gynecologic Oncology, Nashville, Tennessee, March 3-7, Abstract 109.
- Erkanli S., Bolat F., Kayaselcuk F., Demirhan B. and Kuscu E. (2007). COX-2 and survivin are overexpressed and positively correlated in endometrial carcinoma. *Gynecol. Oncol.* 104, 320-325.
- Faloppa C.C., Baiocchi G., Cunha I.W., Fregnani J.H., Osorio C.A.B.T., Fukazawa E.M., Kumagai L.Y., Badiglian-Filho L., Pinto G.L. and Soares F.A. (2014). NF- κ B and COX-2 expression in nonmalignant endometrial lesions and cancer. *Am. J. Clin. Pathol.* 141, 196-203.
- Ferrandina G., Legge F., Ranelletti F.O., Zannoni G.F., Maggiano N., Evangelisti A., Mancuso S., Scambia G. and Lauriola L. (2002). Cyclooxygenase-2 expression in endometrial carcinoma: correlation with clinicopathologic parameters and clinical outcome. *Cancer* 95, 801-807.
- Fordyce C., Fessenden T., Pickering C., Jung J., Singla V., Berman H. and Tlsty T. (2010). DNA damage drives an activin A-dependent induction of cyclooxygenase-2 in premalignant cells and lesions. *Cancer Prev. Res.* 3, 190-201.
- Greenlee R.T., Murray T., Bolden S. and Wingo P.A. (2000). Cancer statistics. *Cancer. J. Clin.* 50, 7-33.
- Horrée N., van Diest P.J., Sie-Go D.M. and Heintz A.P. (2007). The invasive front in endometrial carcinoma: higher proliferation and associated derailment of cell cycle regulators. *Hum. Pathol.* 38, 1232-1238.
- Jarzabek K., Koda M., Walentowicz-Sadlecka M., Grabiec M., Laudanski P. and Wolczynski S. (2013). Altered expression of ERs, aromatase, and COX2 connected to estrogen action in type 1 endometrial cancer biology. *Tumour Biol.* 34, 4007-4016.
- Kosmas K., Mitropoulou G., Stamoulas M. and Marouga A. (2020) Expression of cyclooxygenase-2 in imprint smears of endometrial carcinoma. *Diagn. Cytopathol.* 48, 1086-1092.
- Lambropoulou M., Alexiadis G., Limberis V., Nikolettos N. and Tripsianis G. (2005). Clinicopathologic and prognostic significance of cyclooxygenase-2 expression in endometrial carcinoma. *Histol. Histopathol.* 20, 753-759.
- Li J., Lu Y. and Ma D. (2002). Cyclooxygenase-2 expression in endometrium carcinoma. *Zhonghua Fu. Chan. Ke. Za. Zhi.* 37, 408-410.
- Li M., Li M., Wei Y. and Xu H. (2020). Prognostic and clinical significance of cyclooxygenase-2 overexpression in endometrial cancer: A meta-analysis. *Front. Oncol.* 10, 1202.
- Lyndin M., Kravtsova O., Sikora K., Lyndina Y., Kuzenko Y., Awuah W.A., Abdul-Rahman T., Hyriavenko N., Sikora V and Romaniuk A. (2022). COX2 Effects on endometrial carcinomas progression. *Pathol. Res. Pract.* 17, 238.
- Nasir A., Boulware D., Kaiser H.E., Lancaster J.M., Coppola D., Smith P.V., Hakam A., Siegel S.E. and Bodey B. (2007). Cyclooxygenase-2 (COX-2) expression in human endometrial carcinoma and precursor lesions and its possible use in cancer chemoprevention and therapy. *In Vivo* 21, 35-43.
- Oplawski M., Dziobek K., Zmarzły N., Grabarek B.O., Kielbasiński R., Kieszowski P., Januszyk P., Talkowski K., Schweizer M., Kras P., Plewka A. and Boroń D. (2020). Variances in the level of COX-2 and iNOS in different grades of endometrial cancer. *Curr. Pharm.*

Expression of P16 and COX-2 in endometrial cancer

- Biotechnol. 21, 52-59.
- Orejuela F.J., Ramondetta L.M., Smith J., Brown J., Lemos L.B., Li Y. and Hollier L.M. (2005). Estrogen and progesterone receptors and cyclooxygenase-2 expression in endometrial cancer, endometrial hyperplasia, and normal endometrium. *Gynecol. Oncol.* 97, 483-488.
- Ressler S., Bartkova J., Niederegger H., Bartek J., Scharffetter-Kochanek K., Jansen-Dürr P. and Wlaschek M. (2006). p16INK4A is a robust *in vivo* biomarker of cellular aging in human skin. *Aging Cell* 5, 379-389.
- Reuschenbach M., Waterboer T., Wallin K.L., Eienkel J., Dillner J. and Hamsikova E. (2008). Characterization of humoral immune responses against p16, p53, HPV16 E6 and HPV16 E7 in patients with HPV-associated cancers. *Int. J. Cancer* 123, 2626-2631.
- Sales K.J., Maudsley S. and Jabbour H.N. (2004). Elevated prostaglandin EP2 receptor in endometrial adenocarcinoma cells promotes vascular endothelial growth factor expression via cyclic 3',5'-adenosine monophosphate-mediated transactivation of the epidermal growth factor receptor and extracellular signal-regulated kinase 1/2 signaling pathways. *Mol. Endocrinol.* 18, 1533-1545.
- Sood A., Buller R. and Burger R. (1997). Value of preoperative CA-125 level in the management of uterine cancer and prediction of clinical outcome. *Obstet. Gynecol.* 90, 441-447.
- Steinbakk A., Gudlaugsson E., Aasprong O.G., Skaland I., Malpica A., Feng W., Janssen E.A. and Baak J.P. (1997). Molecular biomarkers in endometrial hyperplasias predict cancer progression. *Am. J. Obstet. Gynecol.* 204, e1-12.
- Tong B.J., Tan J., Tajeda L., Das S.K., Chapman J.A., DuBoist R.N. and Dey S.D. (2000). Heightened expression of cyclooxygenase-2 and peroxisome proliferator-activated receptor in human endometrial adenocarcinoma. *Neoplasia* 2, 483-490.
- Uotila P.J., Erkkola R.U. and Klemi P.J. (2002). The expression of cyclooxygenase-1 and -2 in proliferative endometrium and endometrial adenocarcinoma. *Ann. Med.* 34, 428-433.
- Xiao Y.T., Luo L.M. and Zhang R. (2015). Effect of lentivirus mediated cyclooxygenase-2 gene shorthairpinRNA on invasiveness of endometrial carcinoma. *Eur. J. Gynaecol. Oncol.* 36, 44-48.
- Ye Y., Wang X., Jeschke U. and von Schönfeldt V. (2020). COX-2-PGE2-EPs in gynecological cancers. *Arch. Gynecol. Obstet.* 301, 1365-1375.
- Yoon G., Koh C.W., Yoon N., Kim J.Y. and Kim H.S. (2017). Stromal p16 expression is significantly increased in endometrial carcinoma. *Oncotarget* 8, 4826-4836.
- Zhu J., Mayr D., Kuhn C., Mahner S., Jeschke U. and von Schönfeldt V. (2018). Prostaglandin E2 receptor EP1 in healthy and diseased human endometrium. *Histochem. Cell Biol.* 149, 153-160.
- Zou R., Zheng M., Tan M., Xu H., Luan N. and Zhu L. (2020). Decreased PTGDS expression predicting poor survival of endometrial cancer by integrating weighted gene co-expression network analysis and immunohistochemical validation. *Cancer Manag. Res.* 112, 5057-5075.

Accepted July 19, 2023